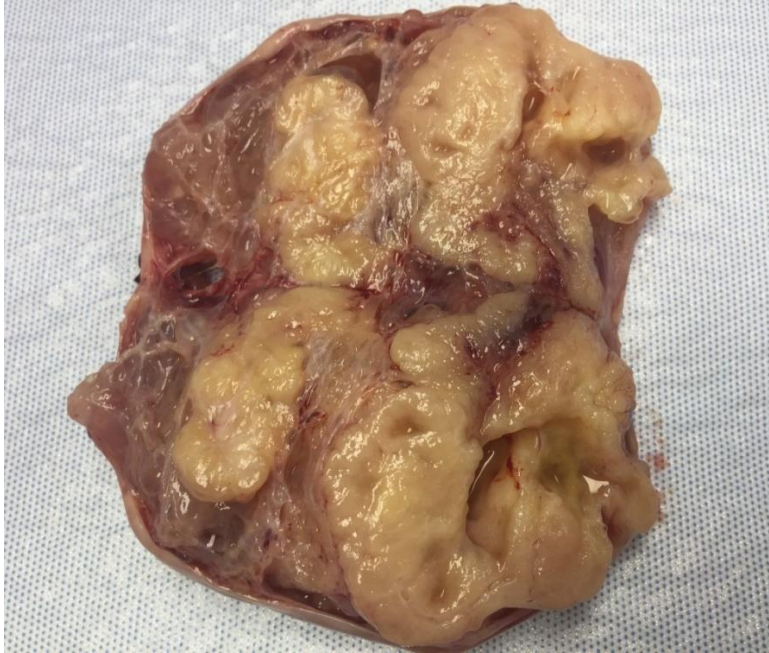




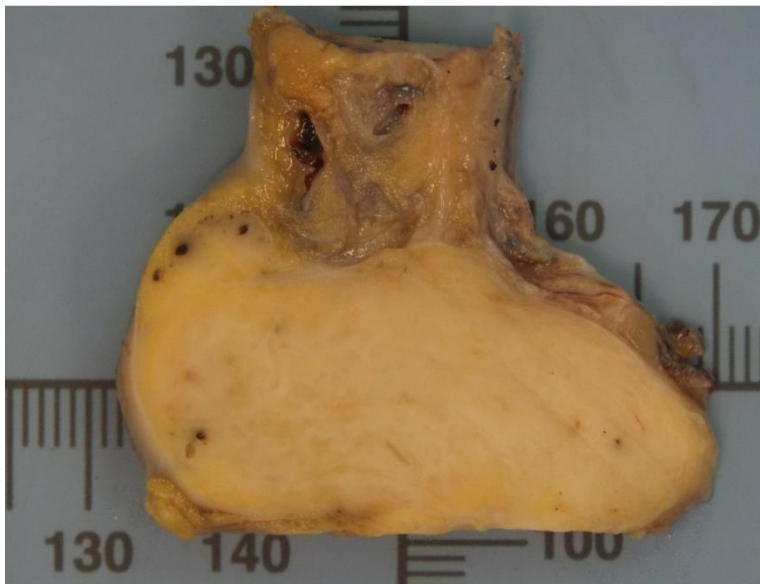4.- GALERIA DE IMAGENES

GINECOLOGIA. Dr. Severino Rey

1- Tumor de brenner maligno

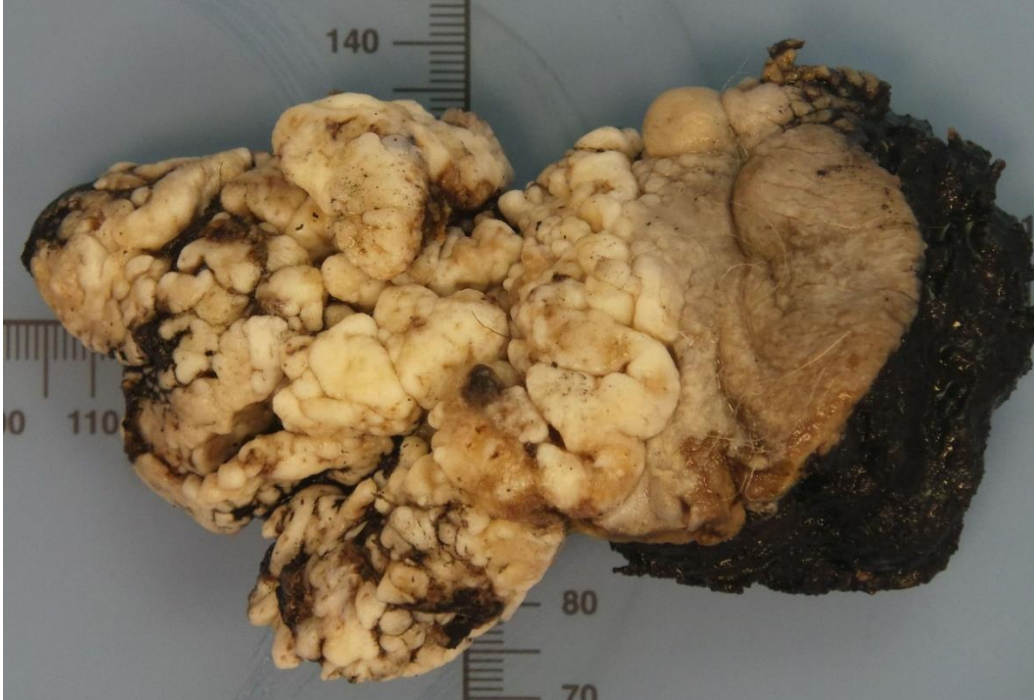

2- Tecoma ovarico

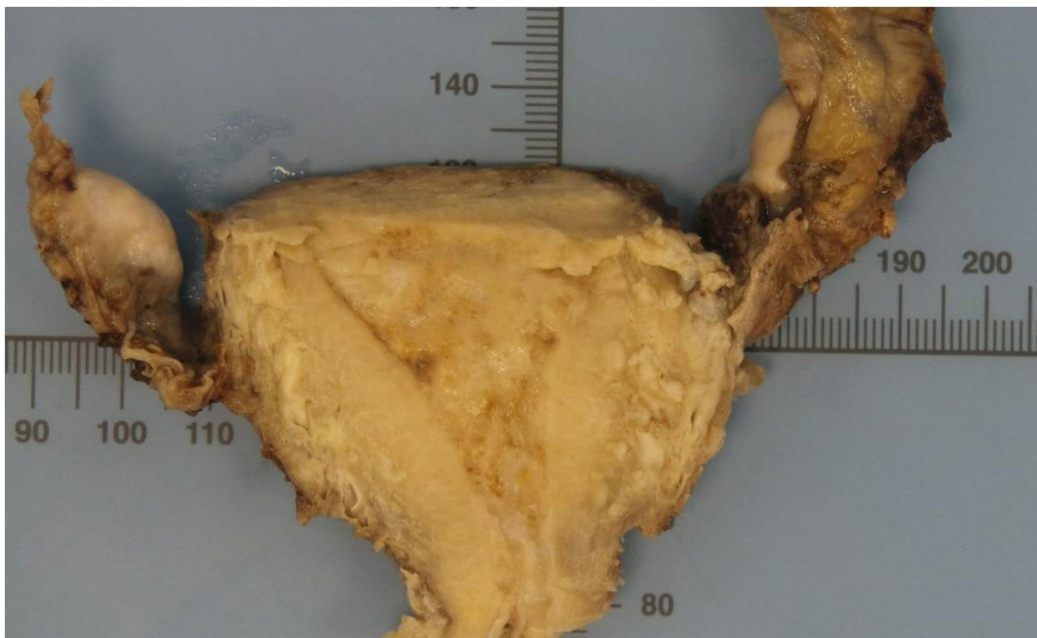




3- Vulvectomía por carcinoma escamoso verrucoso (p16+++)



4- Carcinoma endometrial invasor que perfora la pared miometrial



Reconocimiento-NoComercial-SinObraDerivada 3.0 España (CC BY-NC-ND 3.0 ES)

This Work is licensed under a Creative Commons Attribution-NonCommercial-NoDerivs 3.0 Unported License